E-ISSN: 2708-1508
P-ISSN: 2708-1494
IJCRS 2023; 5(1): 24-27
www.casereportsofsurgery.com
Received: 02-12-2022
Accepted: 18-01-2023

Dema Adwan
Ph.D., Department of Obstetrics and Gynecology, Damascus University of Obstetrics and Gynecology, Damascus, Syria

Solaiman Al-marrawi
MD, Department of Obstetrics and Gynecology, Damascus University of Obstetrics and Gynecology, Damascus, Syria

Aya Takla
MD, Department of Obstetrics and Gynecology, Damascus University of Obstetrics and Gynecology, Damascus, Syria

Ameena Odeh
MD, Faculty of Medicine, Syrian Private University, Damascus, Syria

Wasim Alnjjad
MD, Department of Obstetrics and Gynecology, Damascus University of Obstetrics and gynecology, Damascus, Syria

Ayat Ebrahim
MD, Department of Obstetrics and Gynecology, Damascus University of Obstetrics and Gynecology, Damascus, Syria

Corresponding Author:
Dema Adwan
Ph.D., Department of Obstetrics and Gynecology, Damascus University of Obstetrics and Gynecology, Damascus, Syria

Giant mature ovarian teratoma case report

Dema Adwan, Solaiman Al-marrawi, Aya Takla, Ameena Odeh, Wasim Alnjjad and Ayat Ebrahim

DOI: https://doi.org/10.22271/27081494.2023.v5.i1a.75

Abstract
Germ cell tumors are malignant (cancerous) or nonmalignant (benign, noncancerous) tumors that are comprised mostly of germ cells, the cells that develop in the embryo and become the cells that make up the reproductive system in male and female. Most ovarian tumors are of germ cell origin. A 18-year-old virginal Syrian female was taken to the emergency Department at Damascus university of obstetrics and gynecology on 31.1.2023 with gradual distension of abdomen which had been noticed by parents for the last 6 months. As bedside ultrasonography (USG) showed mixed echogenic mass in the lower abdomen, CT scan of abdomen was requested for further delineation. CT scan of abdomen done on 1.2.2023 showed a giant (about 13×23×26 cm) mixed density mass with homogenously enhancing well defined borders in the abdomen extending from the pelvic cavity to the epigastric region and crossing the medial line causing significant pressure effect downwards towards urinary bladder and contrast material filled guts outwards and backwards mostly occupying the anterior part of abdominal cavity. The tumor was removed surgically and diagnosed as ovarian teratoma histopathologically.

Keywords: Giant mature ovarian teratoma, germ cell, GCT

Introduction
The word "teratomas" is delivered from the Greek language (which the word *terato* means "a monster" and *onkoma* means "mass or swelling") [1]. Teratomas are germ cell tumours (GCT) that derive from germ layers which are: ectoderm, mesoderm and endoderm [2]. The World Health Organization divided the classification of GCT into mature and immature teratoma [3]. Almost 95% of GCT are mature teratomas and 30% of it located in ovaries, so it is considered the most common benign ovarian tumor in childhood and adolescent [4]. Furthermore, these tumors are usually asymptomatic and they diagnosed coincidentally, but clinical manifestation such as abdominal or pelvic pain and ovarian torsion may occur [5]. Mature teratomas usually known as small tumors, they diagnosed easily due to the development of radiological investigation and it is very rare to see a teratoma larger than 10 cm [6]. Here, we present a case of a giant mature ovarian teratoma.

Case presentation
An 18 year-old virginal Syrian female came to the emergency Department at Damascus university of obstetrics and gynecology on 31.1.2023 complained of a feeling of heaviness in the lower abdomen associated with abdominal pain, loss of appetite, fatigue, and weakness for the past 7 days. In Addition, gradual distension of abdomen which had been noticed by parents for the last 6 months. She had regular menstruation and no remarkable medical or surgical history.

No abnormalities were noted on physical examination. She was hemodynamically stable and her vital signs were within normal range. Her laboratory investigation results showed increasing in the tumor marker CA125 and PCT levels, while there were decreasing in HCG and UREA levels. There values were 69.43U/ml, 0.325% 0.24mlU/ml and 16mg/dl, respectively. The rest of the results were normal.

A pelvic ultrasound was performed and showed a cystic adnexal mass on the left ovary with regular margins containing turbid fluid, hyperechogenic formation and calcification. It was 11×11.5×15 cm in size. The right ovary and uterus were normal. Minimal free pelvic fluid was also noted, Figure 1.

In addition, an abdominal computed tomography (CT) was performed on 1.2.2023, which revealed a large cystic lesion in the left ovary with fatty and calcified components within, and extending from the left adnexa to the epigastric region and crossing the medial line. It had a size of 13×23×26 cm, Figure 2.

Surgical intervention was necessary, so the patient was scheduled for surgery the following week. For initial care, 2 crossed blood units with 2 plasma units were arranged, and a general surgeon was informed of the condition in case of unpleasant complications.

A laparotomy was performed for complete removal of the left cystic adnexal mass along with the left ovary through a Midline incision, Figure 3. The specimen was taken to a histopathology laboratory along with a sample of free pelvic fluid. However, the right ovary was left without any intervention.

The histopathology report described mature and benign tissues such as smooth muscle, bronchi, adipose tissue, mucosal glands, nerves, and cartilage lined by benign squamous epithelium. The free pelvic fluid showed no evidence of malignant cells. All of these findings led to the final diagnosis of a mature, benign teratoma with no malignant or immature component, Figure 4.

The patient recovered completely after surgery and no complications occurred, so she could be discharged in stable condition after several days.

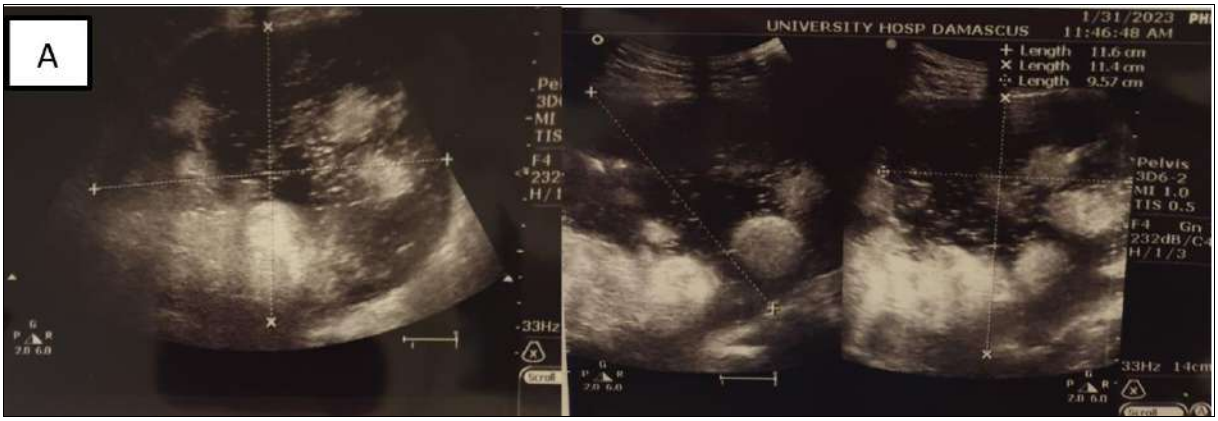

A. A cystic adnexal mass on the left ovary with regular margins containing turbid fluid, hyperechogenic formation and calcification

B. The right ovary and uterus are normal

Fig 1: Axial transabdominal US image

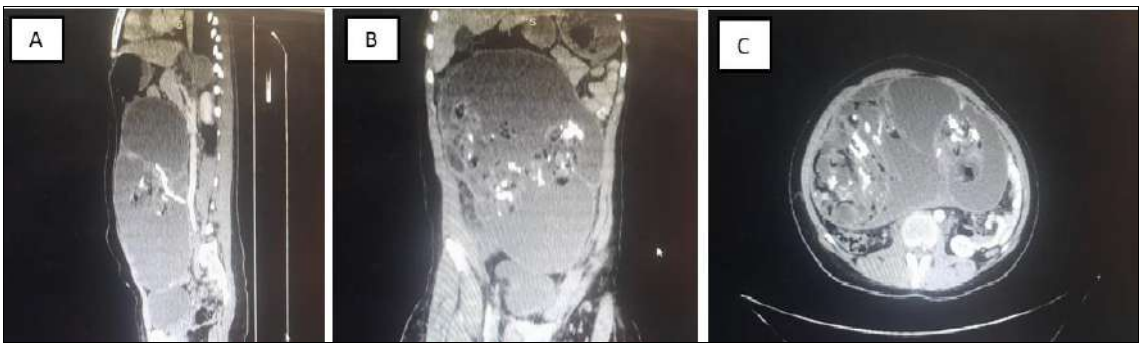

Fig 2: CT Scan with contrast. (A): abdominal sagittal section shows a large teratoma with mixed densities contain cystic component, calcification and other tissues. (B): coronary section shows the abdominal pelvic extension of the teratoma. (C): axial section shows the varies component of the lesion (cystic, adipose, histological structures and calcification). In note, the non-invasive between the teratoma and the nearby organs

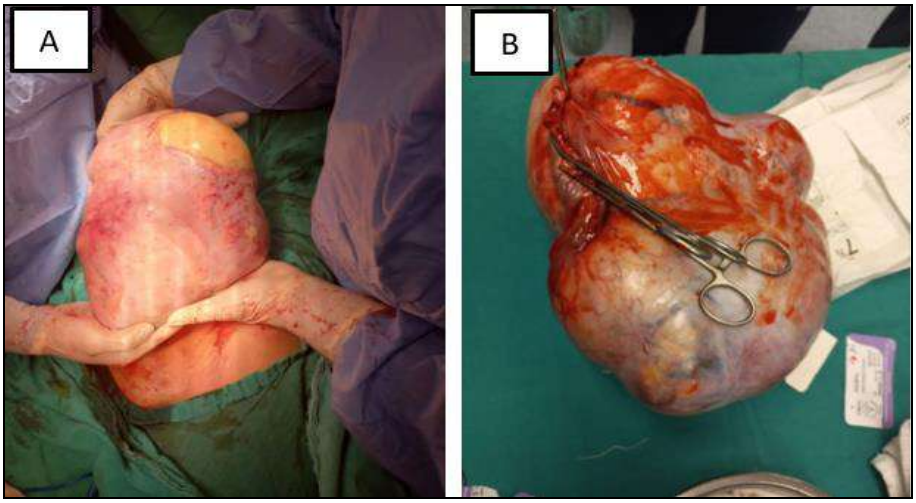

Fig 3: A, B Intraoperative pictures of the mature ovarian teratoma

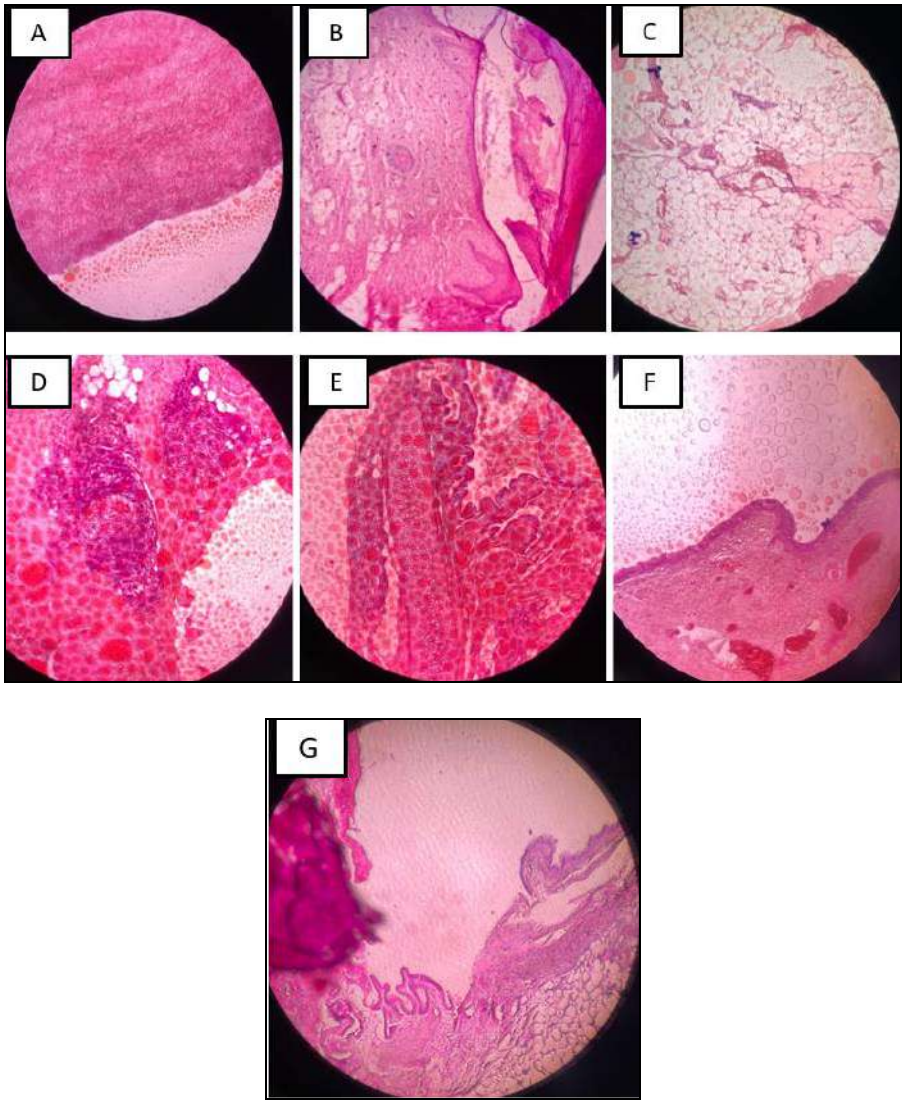

Fig 4: Histopathologycal report of ovarian teratoma with mature structures. (A): smooth muscle tissue and fibroblast. (B): epidermis epithelium. (C): adipose tissue. (D): epidermis neural tissue. (E): cartilage with respiratory epithelium. (F): stratified squamous epithelium. (G): glandular tissue

Discussion

Mature teratomas are the most common benign ovaries tumor occur in childhood and adolescent, they account 95% of GCT and 30% of it occupied in ovaries [4]. It arise from one or more germ cell layers which are: ectoderm, mesoderm and endoderm [2]. Each layer had distinctive components such as epidermis, hair and nerves are ectoderm components [4]. On the other hand, muscles, fat tissue and bone are mesoderm components while, respiratory and gastrointestinal tracts consider as endoderm components [4].

In our case, the mature teratoma contained elements of muscle, fat tissue, cartilages, bronchi, nerve tissue and epidermis so it was derived from all the 3 layers.

A theory suggests that ovarian germ cell tumors in general and teratomas in particular may develop directly from oocytes. It is believed that mature teratomas of the ovary result from parthenogenetic activation of post-first-meiotic germ cells. The mechanisms of ovarian parthenogenetic activation have not been fully clarified; however, a relationship with mutation of the proto-oncogene c-mos has been reported. As many as 30% of c-mos knockout mice develop ovarian teratomas, another theory explains teratomas is abnormal differentiation of fetal germ cells that originate from the fetal yolk sac [1, 7].

Clinical presentation is usually asymptomatic, but it can manifest as an abdominal pain in 70-80% of cases or as a mass in lower abdomen. Indeed, nearby organs can be affected or compressed if the tumor grows to very large sizes which lead to difficulty in distinguishing the diagnosis [5, 1]. In note, 60% of mature teratomas are between 5-10 cm while, only 10% of it are larger than 15 cm [8]. They identify as giant mature teratoma if they measuring larger than 15 cm [6]. In our case, the mature teratoma diameters were 26 ×23 ×13 cm so it recognized as giant mature ovarian teratoma.

Radiological investigation plays a big role in diagnosis the mature teratoma especially the ultrasound. It became the initial investigation for detection echogenic sebaceous structure and calcification which are the most common finding in teratomas. However, Computed tomography (CT) and magnetic resonance imaging (MRI) can be used for evaluation too, because of their sensitivity to fat components in teratomas [9].

Surgical intervention is the main choice for mature teratoma management due to it encapsulated and non-invasion structure [2]. Since the majority of mature teratoma are children and adolescent, it is essential to aim toward conservation ovarian surgery to prevent any puberty disorder [1].

Conflict of Interest
Not available

Financial Support
Not available

References

1. Anton-Păduraru, Dana-Teodora, *et al*. Ovarian teratoma in a teenager causing ureterohydronephrosis: Case report and literature review. Medicine. 2021;100(27):e26472. Doi:10.1097/MD.0000000000026472
2. Bhuiyan HU, Afsana F, Yasmin S, Begum K. A Case of Childhood Ovarian Teratoma. Journal of Enam Medical College. 2012;2(2):94-96. https://doi.org/10.3329/jemc.v2i2.12846
3. Heo Suk Hee, *et al*. Review of ovarian tumors in children and adolescents: radiologic-pathologic correlation. Radiographics: A review publication of the Radiological Society of North America, Inc. 2014;34(7):2039-55. Doi: 10.1148/rg.347130144.
4. AlEssa A, AlAhmadi HH, Ahmed A, *et al*. Well-differentiated cerebellum in an ovarian mature cystic teratoma: a case report and review of the literature. J Med Case Reports. 2022;16(1):215. https://doi.org/10.1186/s13256-022-03444-1
5. Gkrozou Fani, *et al*. Ovarian Teratomas in Children and Adolescents: Our Own Experience and Review of Literature. Children (Basel, Switzerland). 2022 Oct 18;9(10):1571. Doi: 10.3390/children9101571
6. Torabi H, Shirini K, Ashoorian Y, Ghaffari R. A rare case of huge mature ovarian cystic teratoma: A case report. Authorea Preprints; c2022. DOI: 10.22541/au.165648435.57113661/v1.
7. Kuno Naohiko, *et al*. Mature ovarian cystic teratoma with a highly differentiated homunculus: a case report. Birth defects research. Part A, Clinical and molecular teratology. 2004;70(1):40-46. Doi: 10.1002/bdra.10133
8. Ayhan A, *et al*. Mature cystic teratomas of the ovary: case series from one institution over 34 years. European journal of obstetrics, gynecology, and reproductive biology. 2000;88(2):153-157. Doi: 10.1016/s0301-2115(99)00141-4
9. Tsalkidou EG, Memet IH, Chasan GM. Ovarian cystectomy for huge mature cystic teratoma devel-oped in less than five years: A case report. Gynecol Obstet Res Open J. 2016;2(5):99-101.

How to Cite This Article
Adwan D, Al-marrawi S, Takla A, Odeh A, Alnjjad W, Ebrahim A. Giant mature ovarian teratoma case report. International Journal of Case Reports in Surgery. 2023;5(1):24-27.

Creative Commons (CC) License
This is an open access journal, and articles are distributed under the terms of the Creative Commons Attribution-NonCommercial-ShareAlike 4.0 International (CC BY-NC-SA 4.0) License, which allows others to remix, tweak, and build upon the work non-commercially, as long as appropriate credit is given and the new creations are licensed under the identical terms.