



E-ISSN: 2708-1508  
P-ISSN: 2708-1494  
IJCRS 2022; 4(2): 08-10  
[www.casereportsofsurgery.com](http://www.casereportsofsurgery.com)  
Received: 10-05-2022  
Accepted: 07-06-2022

**Dr. Wenlin Wang**  
Professor, Department of  
Chest Wall Surgery,  
Guangdong Second Provincial  
General Hospital, Guangzhou,  
China

**Dr. Weiguang Long**  
Associate Professor,  
Department of Chest Wall  
Surgery, Guangdong Second  
Provincial General Hospital,  
Guangzhou, China

**Dr. Yang Liu**  
Resident Doctor, Department  
of Chest Wall Surgery,  
Guangdong Second Provincial  
General Hospital, Guangzhou,  
China

**Dr. Bin Cai**  
Resident Doctor, Department  
of Chest Wall Surgery,  
Guangdong Second Provincial  
General Hospital, Guangzhou,  
China

**Dr. Juan Luo**  
Resident Doctor, Department  
of Chest Wall Surgery,  
Guangdong Second Provincial  
General Hospital, Guangzhou,  
China

**Corresponding Author:**  
**Dr. Wenlin Wang**  
Professor, Department of  
Chest Wall Surgery,  
Guangdong Second Provincial  
General Hospital, Guangzhou,  
China

## Minimally invasive surgery for flat chest: Wung procedure + Wenlin procedure

**Dr. Wenlin Wang, Dr. Weiguang Long, Dr. Yang Liu, Dr. Bin CAI and Dr. Juan Luo**

### Abstract

Flat chest is a special thoracic deformity, which is mainly characterized by flat anterior chest wall. Because the deformity may be combined with mild depression, Nuss procedure was used in the past. However, due to the lack of appropriate fulcrum, this kind of surgery often ends in failure. We designed a special method to treat this deformity. First, we use Wung procedure to change the figure of anterior chest wall into the shape of middle protrusion and bilateral depression, and then we use Wenlin procedure to perform micro-plastic surgery for the chest wall. In this process, we made full use of the advantages of template plastic surgery, so that the advantages of the two procedures were fully reflected, and finally achieved satisfactory results. In this paper, we report the use of this method in a young male patient with flat chest.

**Keywords:** Flat chest, wung procedure, wenlin procedure

### Introduction

Flat chest is a common thoracic deformity, which often occurs in thin young men and is often associated with spontaneous pneumothorax [1]. Most patients with flat chest encountered in clinical practice are patients with spontaneous pneumothorax who were accidentally diagnosed when they were treated. Flat chest is harmful to human body in two aspects: one is physiological harm, which is similar to pectus excavatum, mainly because of the compression of the anterior chest wall on the lungs [2, 3]; the second is psychological harm, mainly because of abnormal chest wall appearance. If the harm is obvious, whether it is physical or psychological harm, treatment should be considered. For this special deformity, surgery is the only effective method. In the past, the treatment of this deformity was not satisfactory. Some people used Nuss procedure for the patients, but the effect was not ideal. We designed a special method [4] for it, and treated it with Wung procedure [4] and Wenlin procedure [5] simultaneously. Herein we report the operation of a case of flat chest patient using our method.

### Case Report

The patient, male, 18 years old, was thin and weak, and had no obvious abnormal shape of the chest wall since childhood. After puberty, the height increases rapidly, and the appearance of the chest begins to flatten. He often felt flustered and short of breath after activities, but disappeared after rest. The patient was not satisfied with the appearance of the chest wall and was admitted to our hospital for surgical treatment. Preoperative physical examination showed that the anterior chest wall was flat, the anterior and posterior chest diameters were significantly shortened, and heart beats were visible [Fig 1]. Imaging examination showed that the anterior and posterior chest diameters were shortened and the heart was significantly compressed [Fig 2, 3]. The patient was diagnosed as flat chest. The operation was performed under general anesthesia. The patient was in a supine position with both upper limbs abducted. Two incisions were made on each side of the chest wall respectively. The incisions were located between the axillary midline and the axillary frontline, with a length of about 3cm. The chest wall muscles were dissected to expose the ribs in the incision. Wung procedure was performed through the 4th and 6th intercostals [4]. Two arc-shaped steel bars were inserted into the chest through the incisions and passing the mediastinum. After the steel bars were overturned, the general shaping of the chest wall was completed. At this time, the effect was not satisfactory, because the anterior chest wall was obviously convex, while the lateral chest wall was sunken. In order to obtain more satisfactory results, the third steel bar was used to complete Wenlin procedure at the 5th intercostal level [5].

The protrusion in the middle of the anterior chest wall was pressed down and the sunken ribs on both sides were lifted up to make the chest shape close to be normal. After the fixation of bars, the incision was closed and the operation was completed [Fig 4]. Postoperative X-ray examination showed that the steel bars were well fixed and the shape of the chest was satisfactory [Fig 5]. There were no complications, and the patient was discharged 6 days after operation.

### Discussion

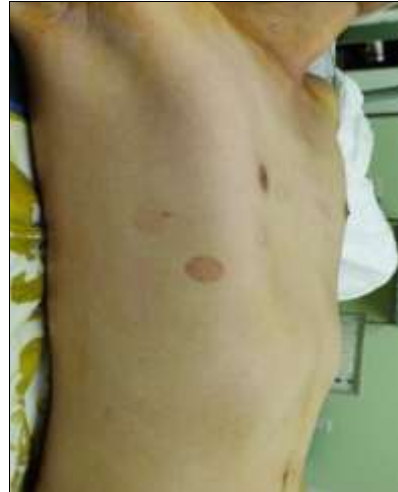The most obvious structural feature of flat chest is the shortening of the anterior and posterior diameter of chest wall [1-3]. The anterior chest wall is always flat, but some patients have mild depression, similar to large-area pectus excavatum, which make some authors use Nuss procedure to treat it. Nuss procedure has a good therapeutic effect on sunken deformities [6]. However, because there is no depression or the depression is not very serious in flat chest, the effect of Nuss procedure is not ideal. Many patients who have Nuss procedure will end up in failure. The cause of failure is mainly related to the principle of Nuss procedure, which is essentially the lever principle. The lever principle requires that the fulcrum should have sufficient height. For Nuss procedure, an ideal fulcrum should be higher than the depression. Since the surrounding ribs of depression in pectus excavatum is relatively higher than the bottom of the depression itself, so these ribs can play the role of fulcrum and Nuss procedure can have therapeutic effect. However, for patients with flat chest, due to the low position of ribs, they cannot play the role of fulcrum, which will lead to the failure of Nuss procedure inevitably. Therefore, for patients with flat chest, Nuss procedure cannot achieve ideal results. In order to treat this deformity successfully, we designed a special method. We combined Wung procedure with Wenlin procedure in the operation. Wung procedure is equivalent to the modified Nuss procedure [4]. Although steel bars are also used to support the chest wall depression, the details of the operation are different. The biggest feature of this procedure is that it can change the shape of the anterior chest wall into an arc-shaped surface. In order to obtain such an effect, it is necessary to deliberately obtain the effect of overcorrection in the correction process, that is, to make the anterior chest wall protrusive in the middle. At this time, the lateral chest wall may be sunken due to the compression of the steel bars. The existence of protrusion and depressions will affect the orthopedic results. In order to eliminate the impact, we used Wenlin procedure for further orthopedics [5]. This operation can not only eliminate the protrusion in the middle, but also eliminate the depressions on both sides, and finally obtain a very ideal effect. Therefore, it is actually a real micro-plastic surgery.

When analyzing the functional principles of various plastic surgeries, we summarize them into three basic types, namely destructive plastic surgery, mechanical external force plastic surgery and template plastic surgery [7]. Wung procedure is a modified Nuss procedure. Just as Nuss procedure, it should also be a typical mechanical external force plastic surgery. However, in the flat chest surgery, due to the over correction method, it also has the characteristics of template plastic surgery. This operation is equivalent to a rough orthopedics. On this basis, Wenlin procedure plays the role of micro-plastic surgery, the principle of which is the standard template plastic surgery, and the effect can be

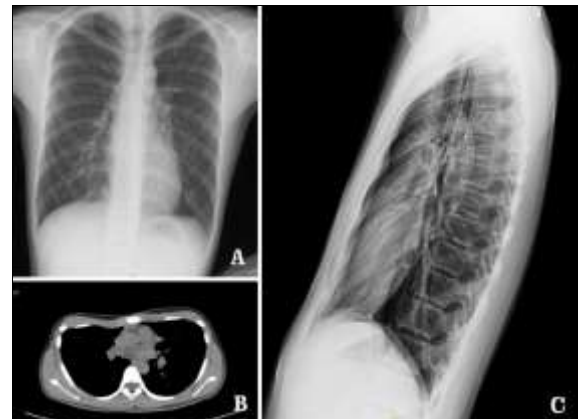guaranteed.

### Conclusion

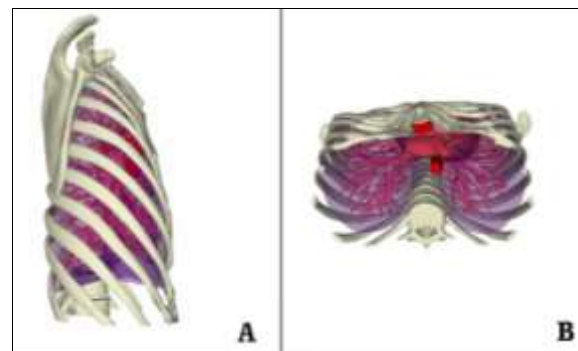
Flat chest is a special thoracic deformity, but cannot be corrected by standard Nuss procedure. We used a combination of two surgical methods to perform the treatment, giving full play to the advantages of template plastic surgery, and finally corrected the deformity. Our experience shows that this method is simple and effective for the treatment of flat chest.



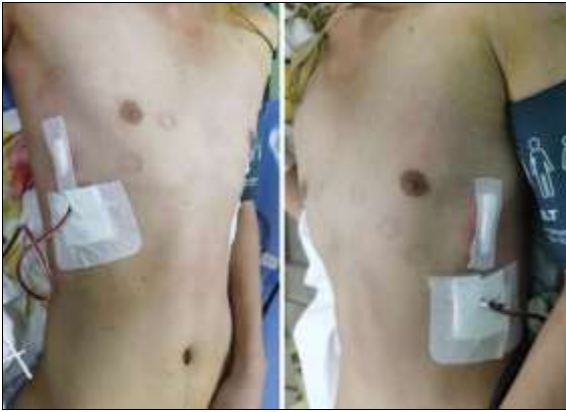**Fig 1:** Appearance of chest wall before operation



**Fig 2:** Imaging examination. A. The X-ray posteroanterior film showed that the costal space was widened; B. CT scanning cross-section showed that the anterior and posterior diameter of thorax was shortened; C. The X-ray lateral film showed that the anterior and posterior diameter of the thorax was shortened



**Fig 3:** The three-dimensional picture of the chest wall showed that the anterior chest wall was flat and the distance between the anterior and posterior diameters was shortened



**Fig 4:** Appearance of chest wall after operation

### Reference

1. Saita K, Murakawa T, Kawano H, Sano A, Nagayama K, Nakajima J. Chest wall deformity found in patients with primary spontaneous pneumothorax. *Asian Cardiovasc Thorac Ann.* 2013;21:582-7.
2. Miyahara S, Chen-Yoshikawa TF, Motoyama H, Nakajima D, Hamaji M, Aoyama A, *et al.* Impact of flat chest on cadaveric lung transplantation: postoperative pulmonary function and survival. *Eur J Cardiothorac Surg.* 2019;55:316-22.
3. De Boeck K, Smith J, Van Lierde S, Van Gijssels D, Devlieger H. Flat chests in survivors of bronchopulmonary dysplasia. *Pediatr Pulmonol.* 1994;18:104-7.
4. Wang W, Long W, Liu Y, Cai B, Luo J. Wung procedure: a minimally invasive operation for pectus excavatum. *International Journal of Case Reports in Surgery.* 2022;4:19-21.
5. Wang W, Long W, Liu Y, Cai B, Luo J. Wenlin procedure: A novel surgical technique for pectus carinatum. *International Journal of Case Reports in Surgery.* 2022;4:10-2.
6. Sakamoto Y, Yokoyama Y, Nagasao T, Yamada Y, Yamada M, Jinzaki M, *et al.* Outcomes of the Nuss procedure for pectus excavatum in adults. *J Plast Reconstr Aesthet Surg.* 2021;74:2279-82.
7. Wang W. Basic theories and concepts of chest wall surgery. *International Journal of Case Reports in Surgery,* 2022, 4.