



International Journal of Case Reports in Surgery

E-ISSN: 2708-1508
P-ISSN: 2708-1494
IJCRS 2022; 4(2): 01-04
www.casereportsofsurgery.com
Received: 04-05-2022
Accepted: 03-06-2022

Dr. Wenlin Wang
Professor, Department of
Chest Wall Surgery,
Guangdong Second Provincial
General Hospital, Guangzhou,
China

Dr. Weiguang Long
Associate Professor,
Department of Chest Wall
Surgery, Guangdong Second
Provincial General Hospital,
Guangzhou, China

Dr. Yang Liu
Resident Doctor, Department
of Chest Wall Surgery,
Guangdong Second Provincial
General Hospital, Guangzhou,
China

Dr. Bin Cai
Resident Doctor, Department
of Chest Wall Surgery,
Guangdong Second Provincial
General Hospital, Guangzhou,
China

Dr. Juan Luo
Resident Doctor, Department
of Chest Wall Surgery,
Guangdong Second Provincial
General Hospital, Guangzhou,
China

Corresponding Author:
Dr. Wenlin Wang
Professor, Department of
Chest Wall Surgery,
Guangdong Second Provincial
General Hospital, Guangzhou,
China

Application of preshaping technique in Wung procedure of severe asymmetric pectus excavatum

Dr. Wenlin Wang, Dr. Weiguang Long, Dr. Yang Liu, Dr. Bin Cai and Dr. Juan Luo

DOI: <https://doi.org/10.22271/27081494.2022.v4.i2a.41>

Abstract

Severe asymmetric pectus excavatum surgery is a technique challenging operation, and it is difficult to obtain good results using general Nuss procedure. In order to ensure the success of the operation, we used a special technique for correction, which is the Wung procedure we designed. Due to the serious deformity, it is very difficult to correct directly. In order to reduce the difficulty, we use a special preshaping technique in our operation, which can fully soften the bony structures of the chest wall in the depression and lay a foundation for the following operation. In addition to this technique, we also made a special design for the position of the steel bars, so as to ensure the final orthopedic effect. This paper reports the application of this technique in a case of severe asymmetric pectus excavatum.

Keywords: Pectus excavatum, Wung procedure, preshaping technique

Introduction

Pectus excavatum is a common thoracic deformity, which may cause physical and psychological harm to patients, so it generally needs surgical treatment [1]. At present, the popular surgical method is Nuss procedure, which has many advantages but also disadvantages [2]. In order to eliminate the disadvantages, some improved methods have been used in clinic [3]. These methods have their own characteristics, but they are not perfect. Our department is the first independent chest wall surgery department in China [4, 5]. Our main work is to complete various chest wall surgeries. Among them, thoracic deformity surgery is our most important work. In all of our patients, pectus excavatum are the most common malformation. In order to get the best treatment for this malformation, we made a substantial improvement on Nuss procedure, and finally designed Wung procedure [1]. Our experience shows that this procedure is a safe and practical minimally invasive surgery. There are many special types of pectus excavatum, and the operation of severe asymmetric pectus excavatum is a very challenging operation. Due to the serious depression, special preshaping technique is needed during the operation, which plays a decisive role in the whole operation process. Additionally, due to the asymmetric position of the depression, other special techniques are needed to ensure the success of the operation. In this paper, we report the preshaping technique and other techniques used in Wung procedure of a patient with severe asymmetric pectus excavatum.

Case Report

The patient, a 25-year-old male, was diagnosed as pectus excavatum with chest wall depression since childhood. He did not receive treatment because he had no symptoms in the early stage. After puberty, the patient's height increased, the depression aggravated, and gradually appeared discomfort. Palpitation and shortness of breath may occur after activities. In addition, the patient began to be dissatisfied with the appearance of chest wall. One year before admission, the patient's symptoms worsened and his desire for surgery was strong, so he was admitted to our hospital for surgery. Preoperative physical examination showed that his anterior chest wall was sunken, and the deepest part of the sunken was located in the right side of the chest wall. His heart beat can be sighted in the left anterior chest wall, and he had mild scoliosis [Fig 1]. Imaging examination showed that the anterior chest wall was sunken, the heart was significantly compressed and shifted to the left, the spine was slightly scoliosis, and the Haller index was 10.2 [Fig 2]. The operation was performed under general anesthesia. Supine position was adopted. Preshaping technique was performed at first. A longitudinal incision was made in front of the xiphoid process with a length of 2cm. The xiphoid process was exposed and cut in the middle, and the dorsal structures beneath the lower end of sternum was freed.

A thyroid retractor was inserted into the gap beneath the end of sternum, and the lower end of the sternum was lifted as much as possible, while the assistant pressed the anterior chest wall to resist the lifting, so that the bony structures of the anterior chest wall at the depression could be softened.

All the above operations were pre-shaping technique. After this technique was completed, two incisions were made on both sides of the chest wall respectively. The incision was located between the anterior axillary line and the middle axillary line, with the length of 2cm. The chest wall muscles in the incision were dissected to expose the surrounding ribs. Two arc-shaped steel bars were inserted into the chest through the incisions, and the steel bars were located at the bottom of the depression. The right ends of the steel bars were placed across one rib, but the left ends were placed at two adjacent ribs directly. After the steel bars were rotated, the depression was propped up. Drainage tubes were placed in bilateral thorax, the incisions were closed, and the operation was completed [Fig 3]. Postoperative imaging examination showed that the thoracic deformity disappeared and the position of the steel bars were normal [Fig 4].

Discussion

The outstanding structural feature of pectus excavatum is the depression of anterior chest wall, and the purpose of surgery is to eliminate the depression. In the early years, the surgery was open operation [6], and the representative operations were Ravitch procedure and sternum turnover operation. These operations had their advantages, but the damage was large and the postoperative scar was long, so they were not ideal choices. In 1998, Nuss announced its design of minimally invasive surgery, which quickly swept the world because of its simplicity and small trauma [2]. However, this kind of operation is not perfect, and it also has obvious disadvantages. In order to eliminate these disadvantages, some improved methods have been used in clinic. Wung procedure is an improved Nuss procedure designed by us, which is different from the classic Nuss procedure in many details [1]. Because some special skills are used in the procedure, it is proved to be a safe and

reliable surgical method.

Although anterior wall depression is the main feature of pectus excavatum, the degree and location of depression are different among various patients, which can be attributed to different types of pectus excavatum. Severe pectus excavatum generally refers to the type with extremely deep depression. This kind of patient's bone is rigid, so it will have great resistance to use the steel bar to support, and it will be very difficult to rotate the steel bar directly. In order to reduce the difficulty, we designed a special technique that is, pre-shaping technique. This technique can soften the bony structures of chest wall in advance, fully release the stress, and make the next rotate operation simple and easy. This technique has a good auxiliary effect on the operation of all deformities with rigid bone, so it is a very important technique.

This patient has a serious deformity and a wide range of lesions. It is impossible to complete the correction with one steel bar, so we used two bars in the operation. This is a common strategy for patients with severe malformations.

Considering the asymmetry of the patient's deformity and the depression on the right side, the details of the operation need to be carefully designed. During the operation, we made a special design for the position of the steel bars. The span of the right ends of the two steel bars is large, which increases the action area to eliminate the obvious depression on the right side. The depression on the left side is not serious, so the distance between the left ends of the steel bars is shortened. After such treatment, the asymmetric depression can be satisfactorily corrected.

At present, there are many treatment methods for asymmetric pectus excavatum. Some authors use asymmetric steel bar for treatment, which can have a good short-term effect, but the long-term effect cannot be guaranteed. The method we designed is different from that of other authors. Due to the obvious increase of the area acted by the steel bars, the effect is more accurate and reliable. In general, our method provides an effective solution for the correction of asymmetric pectus excavatum.

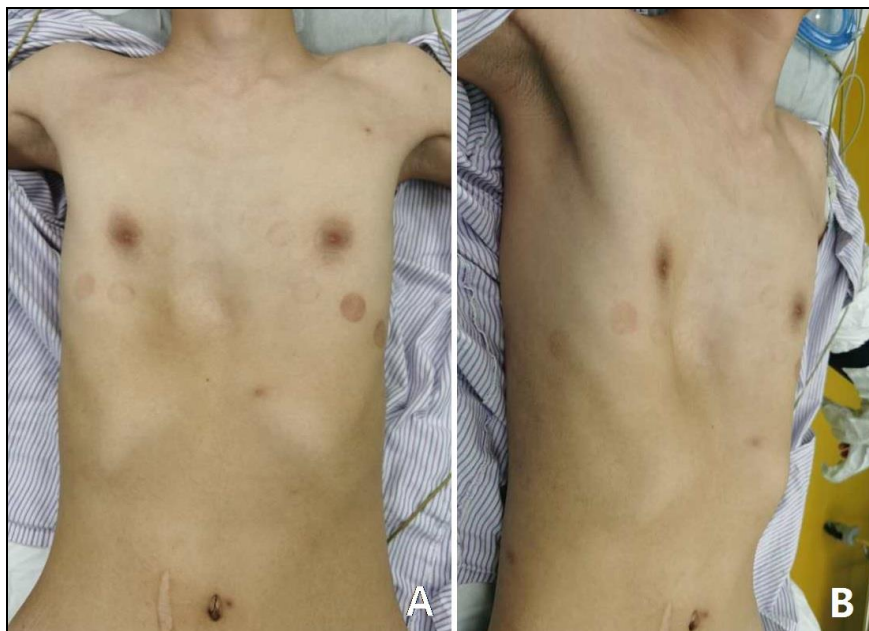

Fig 1: Appearance of chest wall before operation.

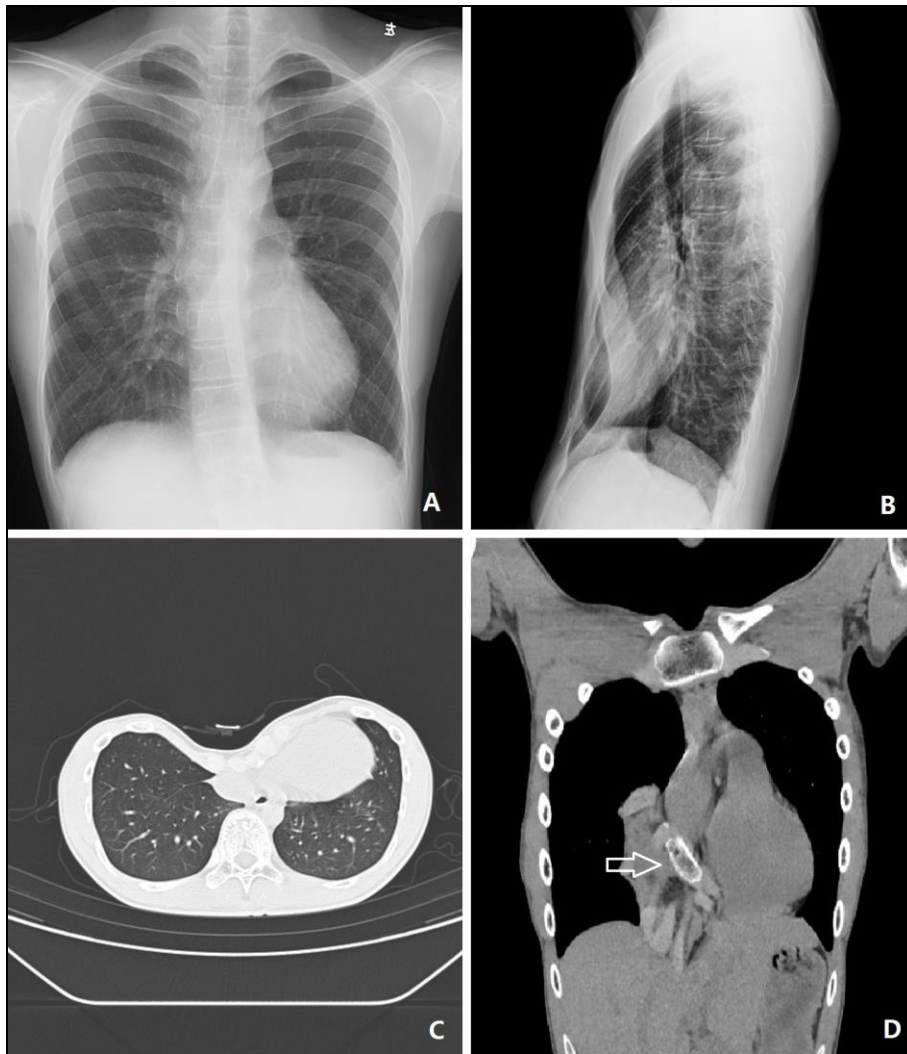


Fig 2: Preoperative imaging examination. The anterior chest wall was sunken, and the heart was compressed and moved to the left.

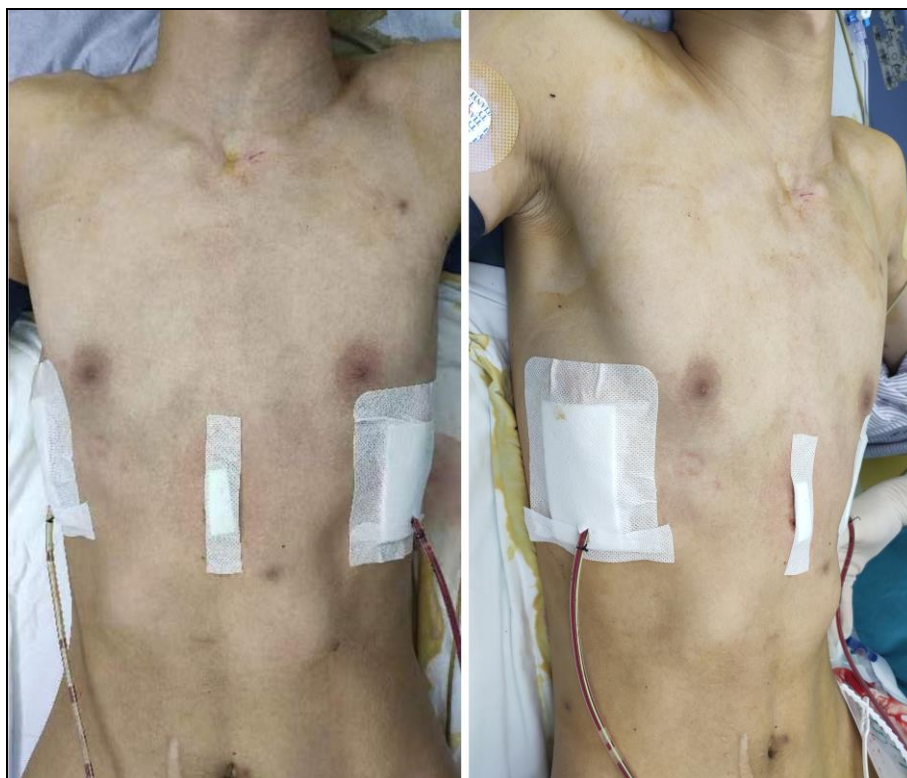

Fig 3: Appearance of chest wall after operation.

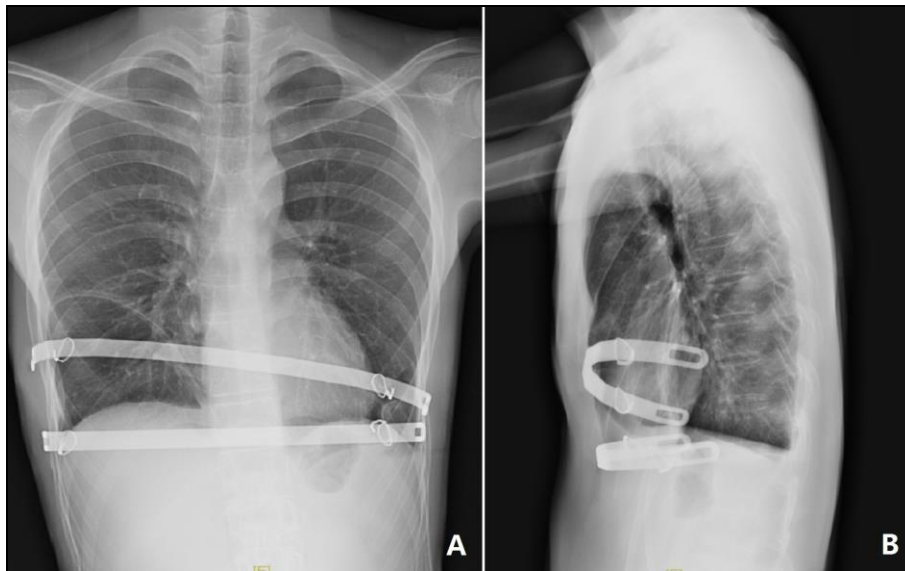


Fig 4: Postoperative X-ray examination. The position of the steel bars were normal, and the chest wall deformity disappeared.

Conclusion

For the deformity of severe asymmetric pectus excavatum, Wung procedure is an ideal choice. Severe depression can be corrected by increasing the number of steel bars, and asymmetric deformities can be corrected by adjusting the position of steel bars. In the whole operation process, the preshaping technique can be an important auxiliary technology for Wung procedure. Without this technique, it may not only increase the difficulty of the operation, but also lead to the direct failure of the operation. Therefore, the preshaping technique is an essential technique for the operation of such deformities.

Reference

1. Wang W, Long W, Liu Y, Cai B, Luo J. Wung procedure: A minimally invasive operation for pectus excavatum. *International Journal of Case Reports in Surgery*. 2022;4:9-21.
2. Sakamoto Y, Yokoyama Y, Nagasao T, Yamada Y, Yamada M, Jinzaki M, *et al.* Outcomes of the Nuss procedure for pectus excavatum in adults. *J Plast Reconstr Aesthet Surg*. 2021;74:2279-82.
3. Jukić M, Mustapić I, Šušnjar T, Pogorelić Z. Minimally Invasive Modified Nuss Procedure for Repair of Pectus Excavatum in Pediatric Patients: Single-Centre Retrospective Observational Study. *Children (Basel)*. 2021;8:1071.
4. Jiang R, Liao L. Wenlin Wang: A “weird doctor” in defiance of the Matthew effect. *J Thorac Dis*. 2019;11:E90-5. Doi: 10.21037/jtd.2019.07.03.
5. Wang W. Basic theories and concepts of chest wall surgery. *International Journal of Case Reports in Surgery*. 2022, 4 (Received).
6. Schwabegger AH. Pectus excavatum repair from a plastic surgeon’s perspective. *Ann Cardiothorac Surg*. 2016;5:501-12.