E-ISSN: 2708-1508
P-ISSN: 2708-1494
IJCRS 2022; 4(1): 22-24
www.casereportsofsurgery.com
Received: 18-11-2021
Accepted: 22-12-2021

Dr. Wenlin Wang
Professor, Department of Chest Wall Surgery, Guangdong Second Provincial General Hospital, Guangzhou, China

Dr. Weiguang Long
Associate Professor, Department of Chest Wall Surgery, Guangdong Second Provincial General Hospital, Guangzhou, China

Dr. Yang Liu
Resident Doctor, Department of Chest Wall Surgery, Guangdong Second Provincial General Hospital, Guangzhou, China

Dr. Bin Cai
Resident Doctor, Department of Chest Wall Surgery, Guangdong Second Provincial General Hospital, Guangzhou, China

Dr. Juan Luo
Resident Doctor, Department of Chest Wall Surgery, Guangdong Second Provincial General Hospital, Guangzhou, China

Corresponding Author:
Dr. Wenlin Wang
Professor, Department of Chest Wall Surgery, Guangdong Second Provincial General Hospital, Guangzhou, China

Morphological characteristics of Wenlin chest

Dr. Wenlin Wang, Dr. Weiguang Long, Dr. Yang Liu, Dr. Bin Cai and Dr. Juan Luo

Abstract
Wenlin chest is a rare thoracic deformity. In the past, this deformity was not well understood and its name was very confused, which seriously affected the treatment of this deformity. We find in our work that this deformity is a completely independent thoracic deformity, which has no connection with the any existing deformities. Morphologically, the most basic lesion of this deformity is from sternum. The sternum angle is convex and the sternum body is sunken, presenting an S-shaped sternum. Due to the obvious change in the sternal shape, the structures of the chest wall connected with the sternum also changed in shape, and finally formed a special deformity with distinctive characteristics. A thorough understanding of this deformity in morphology will not only be conducive to the diagnosis of this deformity, but also to its treatment.

Keywords: Wenlin chest, thoracic deformity, morphology

Introduction
Wenlin chest is a rare thoracic deformity. There have been different opinions on its understanding [1-4]. Some authors regarded it as a kind of pectus carinatum, some authors regarded it as a kind of pectus excavatum, and some other authors even simply regarded it as a composite deformity of the two [4]. When the name of this deformity is considered, some authors called it pigeon breast [1], some authors called it pectus arcuatum [5, 6], but others call it Currarino-Silverman syndrome [3, 4]. The confusion of nomenclature has seriously affected the diagnosis and treatment of this malformation [4]. Our department is an independent chest wall surgery clinical center, specializing in the surgical treatment of various chest wall deformities. In our work, we have treated a large number of patients with this kind of deformity. In order to better understand this deformity, we named it as Wenlin chest [2]. Here we report a case of Wenlin chest and introduce its morphological features, so as to better understand the deformity.

Case Report
The patient, a 25-year-old male, was found to have abnormal appearance of the anterior chest wall since childhood. Before puberty, the deformity was slight, and then gradually became obvious. The patient had no symptoms, but was not satisfied with the appearance of chest wall. He was admitted to our hospital for surgical treatment. Physical examination showed that there was an obvious protrusion on his upper anterior chest wall [Fig 1]. The center of the protrusion was located at the sternal angle, extending to both sides of the chest wall. The lower edge of the protrusion on both sides sagged. There was a depression below the median protrusion. The upper edge and both sides of the depression were formed by the lower edge of the protrusion, the bottom of which was the sternum body. Imaging examination showed that the sternal angle was protrusive and thickened, and the cartilages and ribs connected with it protruded on both sides. The whole sternum presented an "S" shape, and his heart was compressed by the sternal depression and shift to the left [Fig 2, 3, 4, 5]. He was diagnosed as Wenlin chest before operation. We performed surgical treatment for him. A longitudinal skin incision was made at the sternal angle to expose the sternum and costal cartilages on both sides. The anterior protrusion of sternal angle and part of medulla were resected. Additional incisions were made on both chest walls respectively. Two tunnels were made beneath the muscles layer, and two steel bars were placed into the tunnels on the bony protrusion surface to perform Wenlin procedure [7] [Fig 6]. The protrusive part of the structures were flattened, and the bars were fixed on both sides of the lateral chest wall. A tunnel was made at the bottom of the sternal depression, and the Wung procedure was performed with the third steel bar to eliminate the depression [Fig 6]. After the incisions were closed, the operation was completed. After the operation, the deformity was completely

eliminated [Fig 7]. The postoperative recovery was satisfactory without complications, and he was discharged 7 days after operation.

Fig 1: Appearance of chest wall of Wenlin chest patients. The upper middle part of the anterior chest wall is protruded and the lower middle part is sunken.

Fig 2: X-ray posteroanterior image. The abnormal shape of bony structure was not obvious, but the heart moved to the left slightly

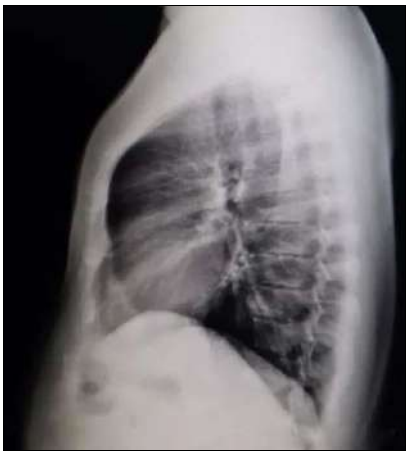

Fig 3: X-ray lateral image. Sternum is S-shaped, and sternal angle is thickened and protruded.

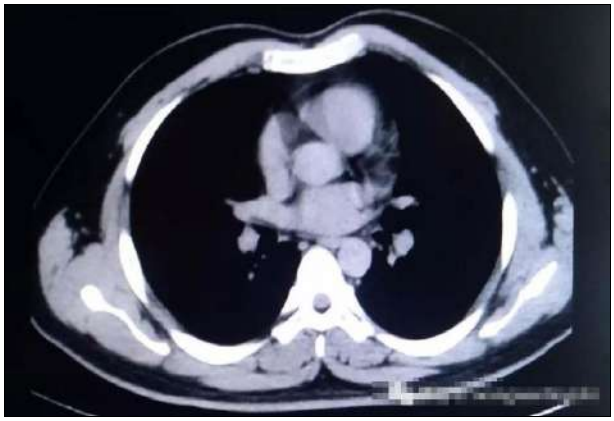

Fig 4: CT scan. Sternum thickness increased and anterior chest wall protruded forward

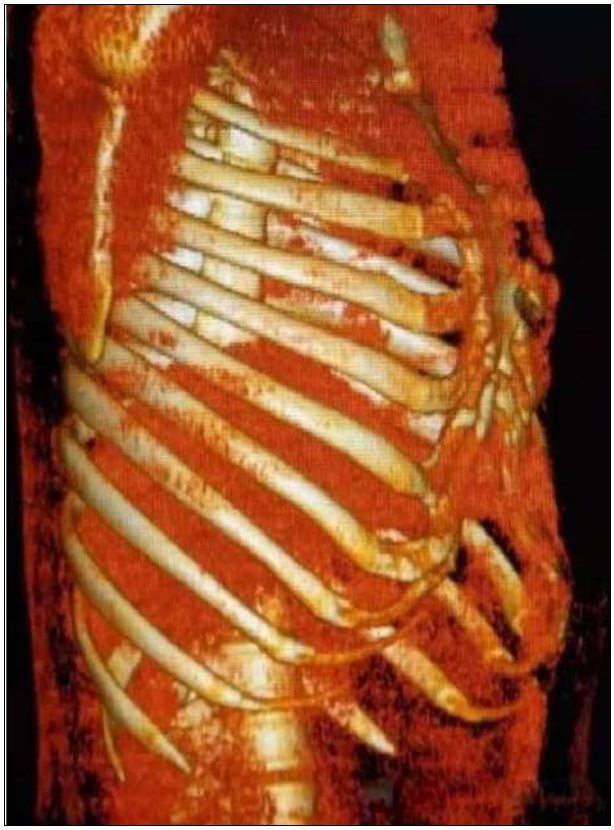

Fig 5: Three dimensional reconstruction structure of thorax. Sternal angle lesion is obvious, and sternum is S-shaped



Fig 6: Three steel bars were used during the operation

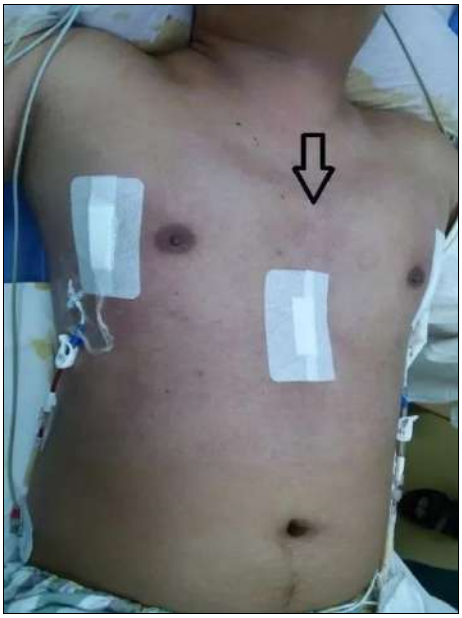

Fig 7: Postoperative chest wall appearance

Discussion

Wenlin chest is a rare thoracic deformity. Due to the confusion of records and various names in the literature, the diagnosis and treatment of this deformity have been seriously affected [2, 4]. Some patients were diagnosed as ordinary pectus carinatum or pectus excavatum and received the corresponding treatment, resulting in the failure of the operation [4]. Obviously, it is necessary to discuss the clinical characteristics and eliminate the misunderstanding of this deformity.

The main feature of Wenlin chest is the abnormality of the sternum. Its overall appearance is S-shaped [2]. There are two places with the most serious lesions, one is the sternal angle and the other is the sternal body. Sternal angle thickened and protruded, forming obvious protrusion, while the sternal body is sunken to form an obvious depression. Because the costal cartilages and ribs of the anterior chest wall are directly or indirectly connected with the sternum, the change of sternum shape will inevitably lead to the change of the overall appearance of the chest wall. This is the root cause of this kind of deformity.

Although there are obvious protrusion and depression in Wenlin chest, it's not a simple sum of pectus carinatum or pectus excavatum, nor is it a general compound deformity. The most fundamental reason lies in the particularity of sternum structure. Due to the thickening and hardness of the sternum, it is difficult to correct by general minimally invasive surgery. At present, the commonly used minimally invasive surgical methods in clinical practice include Nuss procedure [8], Wung procedure, Wenlin procedure [7], Wang procedure [9, 10] or sandwich operation. If these methods are used directly, it will be difficult to get good results.

In the past work, we have designed several surgical methods according to the morphological characteristics of Wenlin chest and achieved satisfactory results. Our experience shows that this deformity is an independent chest deformity, which is neither general pectus carinatum nor pectus excavatum [2]. The recognition of this morphological feature will contribute to the diagnosis and treatment of this deformity.

Conclusion

Wenlin chest is a rare thoracic deformity. The fundamental pathological change lies in the sternum. Due to the change of sternum structure and shape, the entire anterior chest wall has abnormal shape. This deformity is not ordinary pectus carinatum nor pectus excavatum, and even nor a simple sum of these two, but an independent deformity. It is difficult to complete the treatment of this deformity by general minimally invasive operations, and special methods are needed to obtain satisfactory results.

Reference

1. Lester CW. Pigeon breast (*Pectus carinatum*) and other protrusion deformities of the chest of developmental origin. Ann Surg. 1953;137:482-9.
2. Wang W, Long W, Liu Y, Cai B, luo J. Wenlin chest: an independent thoracic deformity. International Journal of case reports in surgery. 2022;4:13-5.
3. Mehta AV. Currarino-Silverman syndrome and congenital heart disease. Tex Heart Inst J. 1996;23:69.
4. Gritsiuta AI, Bracken A, Beebe K, Pechetov AA. Currarino-Silverman syndrome: diagnosis and treatment of rare chest wall deformity, a case series. J Thorac Dis. 2021;13:2968-2978.
5. Kuzmichev V, Ershova K, Adamyan R. Surgical correction of pectus arcuatum. J Vis Surg. 2016;2:55.
6. Kim SY, Park S, Kim ER, Park IK, Kim YT, Kang CH. A case of successful surgical repair for pectus arcuatum using chondrosternoplasty. Korean J Thorac Cardiovasc Surg. 2016;49:214-7.
7. Wang W, Long W, Liu Y, Cai B, luo J. Wenlin procedure: a novel surgical technique for pectus carinatum. International Journal of case reports in surgery. 2022;4:10-12.
8. Nuss D, Obermeyer RJ, Kelly RE. Pectus excavatum from a pediatric surgeon's perspective. Ann Cardiothorac Surg. 2016;5:493-500.
9. Wang W, Chen C, Long W, Li X, Wang W. Wang procedure for treatment of pectus excavatum. SL Clin Exp Cardiolog. 2018;2:113.
10. Wang W, Chen C, Long W, Li X, Wang W. Wang procedure: novel minimally invasive procedure for pectus excavatum children with low age. Case Reports and Images in Surgery. 2018;1:1-2. DOI: 10.15761/CRIS.1000104.