E-ISSN: 2708-1508
P-ISSN: 2708-1494
IJCRS 2022; 4(1): 10-12
www.casereportsofsurgery.com
Received: 06-01-2022
Accepted: 09-03-2022

Dr. Wenlin Wang
Professor, Department of Chest Wall Surgery, Guangdong Second Provincial General Hospital, Guangzhou, China

Dr. Weiguang Long
Associate Professor, Department of Chest Wall Surgery, Guangdong Second Provincial General Hospital, Guangzhou, China

Dr. Yang Liu
Resident Doctor, Department of Chest Wall Surgery, Guangdong Second Provincial General Hospital, Guangzhou, China

Dr. Bin Cai
Resident Doctor, Department of Chest Wall Surgery, Guangdong Second Provincial General Hospital, Guangzhou, China

Dr. Juan Luo
Resident Doctor, Department of Chest Wall Surgery, Guangdong Second Provincial General Hospital, Guangzhou, China

Corresponding Author:
Dr. Wenlin Wang
Professor, Department of Chest Wall Surgery, Guangdong Second Provincial General Hospital, Guangzhou, China

Wenlin procedure: A novel surgical technique for pectus carinatum

Dr. Wenlin Wang, Dr. Weiguang Long, Dr. Yang Liu, Dr. Bin Cai and Dr. Juan Luo

Abstract
Pectus carinatum is a common thoracic deformity, and Abramson technique is the most popular operation for this deformity at present. Although this technique has many advantages, it also has many obvious disadvantages. In order to eliminate these disadvantages, we designed a new operation, i.e. Wenlin procedure. We performed this operation on a patient with severe pectus carinatum and obtained satisfactory results. Our experience shows that Wenlin procedure is an ideal surgical technique for pectus carinatum, but its long-term effect needs further confirmation.

Keywords: Pectus carinatum, wenlin procedure, operation

Introduction
Pectus carinatum is one of the most common thoracic deformities. Its main feature is the protrusion of the anterior chest wall [1, 2]. This kind of deformity may not be harmful to physiological function of the patient, but it can significantly affect the appearance of the chest wall. Many patients are dissatisfied with the appearance and are eager for surgical treatment. The operation of pectus carinatum has a long history. In the early years, the operations were completely open techniques [1, 2]. Until 2005, Abramson reported a special technique, which began the era of minimally invasive treatment of pectus carinatum [3]. However, the design of Abramson technique has obvious disadvantages, and it cannot be used in all pectus carinatum operations [3]. In order to eliminate these disadvantages, we designed a new procedure and used it in a severe pectus carinatum patient. Here we introduce the application of this procedure in my patient.

Case Report
The patient was a 20-year-old male who was admitted to our hospital for protrusion of the chest wall [Fig 1]. In the early childhood of the patient, there was no obvious abnormality in the appearance of the thorax. From the age of 13, the patient's anterior chest wall began to appear abnormal, and then gradually protruded forward, but he had no symptoms. Because the patient was not satisfied with the appearance of the chest wall, he hoped to get surgical treatment. We performed physical and imaging examinations for the patient and found that his chest wall was convex and symmetrical [Fig 1, 2]. He was diagnosed as pectus carinatum before operation. His operation was performed under general anesthesia, and he was in the supine position. A longitudinal incision was made on each side of the chest wall, which was located between the median and anterior axillary lines, and on the highest protrusive plane. The length of the incision was about 2cm. After the muscles in the incision were dissociated, the ribs of the lateral chest wall were exposed. Two horizontal lines were made along the highest protrusive plane, with an interval of 3 cm [Fig 1]. The positions where the ribs cross the horizontal line were marked [Fig 1], and the steel wire traction lines were placed at these positions. Two tunnels were made from both incisions to the middle along the horizontal line, which were located between the muscular layers and the bony structures. Two arc-shaped steel bars were put into the tunnels respectively. The fixed steel wires with introduced by the steel wire traction lines to surround the ribs and the steel bars. After the central protrusion was pressed, the steel wires were tightened and fixed, and the protrusion was eliminated [Fig 3]. After placing drainages in the pleural cavities, the incisions were closed and the operation was completed. The operation was smooth without complications. The operation time was 45 minutes and the bleeding volume was 20ml. The postoperative recovery was satisfactory and the patient was discharged 5 days after operation. The appearance of chest wall was normal postoperatively [Fig 4, 5].

After 15 months of follow-up, there was no discomfort and no change in the appearance of chest wall.

Discussion

Pectus carinatum surgery has a long history. Early operations were totally open techniques [1, 2]. The main contents of operations were cutting off or partially removing the protruding structures, and then making overall corrections to the anterior chest wall. These kinds of operations have large injuries, long postoperative scars, and cannot guarantee satisfactory results [1, 2].

In 2005, Abramson first reported a minimally invasive technique for pectus carinatum [3]. Using a steel bar to compress the protrusion of the anterior chest wall, pectus carinatum could be treated easily with a satisfactory result. After the emergence of this method, the concept of treating pectus carrinatum has been fundamentally changed, and Abramson technique has become the mainstream operation for treating pectus carinatum [3, 4].

Being a minimally invasive procedure, Abramson technique has many advantages compared with open techniques. However, it also has disadvantages [3, 4]: First, it has special requirements for the bone elasticity. It cannot be used for patients with rigid bones and old age; Secondly, it cannot be used in pectus carinatum with local depression. Third, it cannot be used for severe deformities.

In our early operations of pectus carinatum, we have ever used Abramson technique. After we found the disadvantages of this technique, we designed a novel technique and named it as Wenlin procedure. Although this procedure is similar to Abramson technique, there are many differences in details, which makes it has more obvious advantages. These advantages include: (1) The procedure is very simple, and only steel wires are needed to fix the steel bars; (2) Since each end of the steel bar is fixed at two ribs, the medial fixed steel wire can be used to lift the possible local depression, so this procedure can be used to treat more complex deformities; (3) For large-area pectus carinatum, two or even three steel bars can be used to complete the operation, so it can be used in some severe deformities; and (4) For patients with old age or rigid bones, this procedure can be completed by increasing the number of steel bars, therefore, it can be used in more pectus carinatum patients..

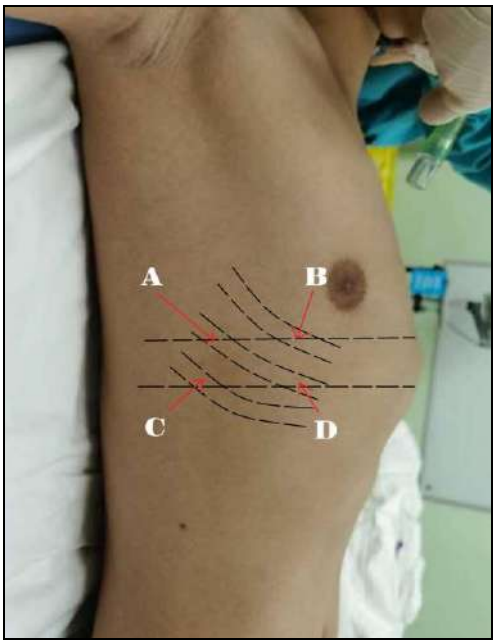

Fig 1: Appearance of chest wall before the operation. A. B, C and D are the intersections of the ribs on the lateral chest wall and the two parallel lines passing through the most convex plane of the anterior chest wall.

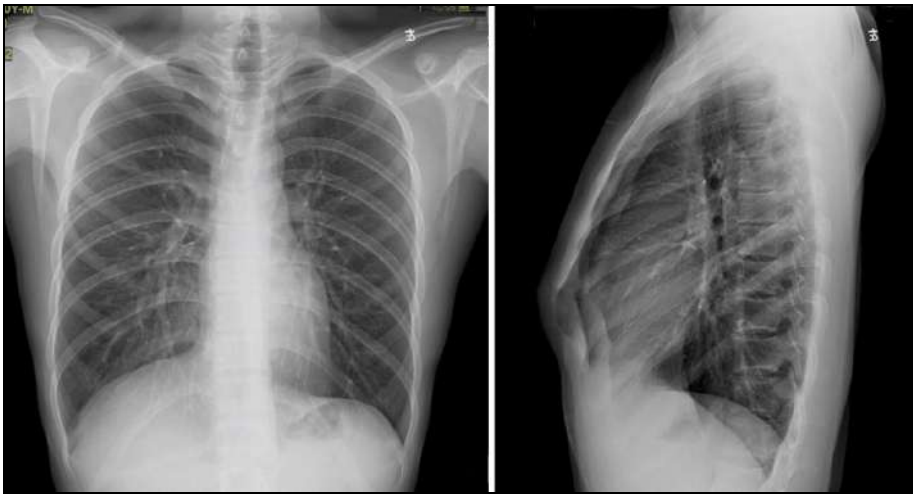

Fig 2: X-ray of the chest before the operation.

Fig 3: Schematic diagram of the operation.

Fig 4: Appearance of chest wall after the operation.

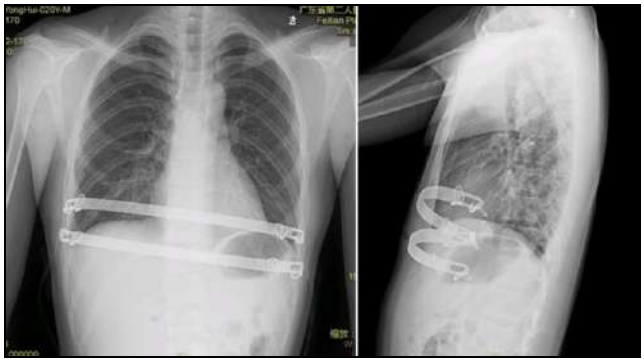

Fig 5: X-ray of the chest after the operation.

Conclusion

Our experience shows that Wenlin procedure is more practical and more effective than Abramson technique. We believe that this is an ideal choice for patients with pectus carinatum. However, its long-term effect needs further observation.

References

1. Lester CW. Surgical Treatment of Protrusion Deformities of the Sternum and Costal Cartilages (Pectus Carinatum, Pigeon Breast). Ann Surg. 1961; 153(3):441-446.
2. Fonkalsrud EW, DeUgarte D, Choi E. Repair of Pectus Excavatum and Carinatum Deformities in 116 Adults. Ann Surg. 2002;236(3):304-314.
3. Abramson H, Aragone X, Blanco JB, Ciano A, Abramson L. Minimally invasive repair of pectus carinatum and how to deal with complications. J Vis Surg. 2016;2(64):1-18.
4. Özkaya M, Bilgin MC. Minimally invasive repair of pectus carinatum by modification of the Abramson technique. Wideochir Inne Tech Maloinwazyjne. 2018;13:383-387.